



Idiopathic Cavernal Abscess: An Uncommon Case Report Abscesso Cavernal Idiopático: Um Caso Clínico Involgar

Pedro Simões de Oliveira*, Tiago Ribeiro de Oliveira, Sandro Gaspar, David Martinho, Francisco Martins, Tomé Lopes

Abstract

Cavernosal abscess is an uncommon condition. It can be idiopathic or with an underlying cause. Surgical drainage and systemic antibiotics remain the first line of treatment regarding long-term sequelae.

*The authors report a rare case of a 51-year-old man with a bilateral cavernosal abscess with no underlying cause. The patient was treated with surgical drainage and systemic antibiotics. Culture of pus was positive for *Staphylococcus aureus*. There were no sequelae at six-month follow-up.*

Keywords: Abscess; Drainage; Penile Diseases.

Introduction

Abscess of the corpus cavernosum is an unusual condition, with few cases reported in the literature. It can be idiopathic or in association with penile trauma,^{1,2} intracavernous injection therapy,³ foreign bodies, priapism, local or disseminated infection or in association with underlying disease such as diabetes. The most commonly implicated organisms include *Staphylococcus aureus*, *Streptococci*, *Fusibacteria* and *Bacteroides*.⁴ First line therapy includes surgical drainage and systemic antibiotics. We report a case of bilateral cavernosal abscess due to *Staphylococcus aureus*, with no identifiable cause, treated successfully with surgical drainage and systemic antibiotics without long-term sequelae.

Case Report

A 51-year-old previously healthy man presented to the Emergency Department (ED) with a 2-week history of worsening perineal and scrotal swelling, local pain, dysuria and weakening of his urinary stream. He had been evaluated at an outside facility and discharged on oral ciprofloxacin. Five days later, due to worsening of the symptoms, fever (40°C) and chills, he presented in our ED. He had no history of prior genitourinary instrumentation, cavernosal injection therapy, or lower urinary tract symptoms as well as unprotected sexual intercourse. There was no evidence of other active infection including dental abscess. On physical examination there was firmness and fluctuance of the perineum and scrotum (Fig. 1). Laboratory tests revealed leukocytosis (14.500/mm³), with 91% neutrophils, C-reactive protein was 13 mg/dL. The remaining chemistries and urine dipstick were unremarkable. A computed tomography (CT) scan of the pelvis showed a fluid collection involving the bilateral cavernosal bodies (Fig. 2). Empiric therapy

Resumo

O abscesso cavernoso é uma patologia involgar. Pode ser idiopático ou de causa conhecida. A drenagem cirúrgica e a antibioterapia sistémica constituem a primeira linha de tratamento, tendo em conta as sequelas a longo prazo.

Os autores apresentam um caso de um homem de 51 anos com abscesso cavernoso bilateral de causa desconhecida. O doente foi tratado com drenagem cirúrgica e antibióticos sistémicos. A cultura de pus foi positiva para *Staphylococcus aureus*. O doente não apresentou sequelas no seguimento a seis meses.

Palavras-chave: Abscesso; Doenças do Pénis; Drenagem.

with piperacilin-tazobactam was initiated and the patient underwent immediate surgical drainage through a midline perineal incision, with pus aspiration and copious washout performed and placement of a Penrose drain. The wound was allowed to heal by second intention, daily dressings were performed and the drain was removed after five days. He completed a 4-week course of intravenous piperacilin-tazobactam and was discharged.

Blood and urine culture yielded no growth. The aspirated pus culture was positive for *Staphylococcus aureus* sensitive to piperacilin-tazobactam, meropenem and amikacin. At six-month follow-up, the patient presented a completely healed wound, without penile deviation and maintained erectile function.

Discussion

Cavernosal abscess is an uncommon condition and has been described in association with penile trauma,^{1,2} intracavernous injection therapy,³ penile foreign bodies including penile prosthesis, priapism, hematological spread of infection from a distant site (ex: peri-odontal abscess) or following perineal or perianal abscess drainage or in association with underlying disease such as diabetes.⁴ Other cases, when no underlying cause is identified, are considered idiopathic, and this condition has been reported very rarely in the literature. Several organisms have been isolated from abscess swabs, and a recent revision of cavernosal abscess case reports by Dugdale *et al* identified *Staphylococcus aureus*, *Streptococci*, *Fusibacteria* and *Bacteroides* as the most common causal organisms. In our reported case, there was no identifiable cause, hence titled as idiopathic cavernosal abscess. *Staphylococcus aureus* was isolated as the causal organism, which is one of the most common. The decision of empiric therapy with piperacilin-tazobactam was based on the worsening of the symptoms under ciprofloxacin, including high fever, and the suspicion

Serviço de Urologia, CHLN - Hospital de Santa Maria, Lisboa

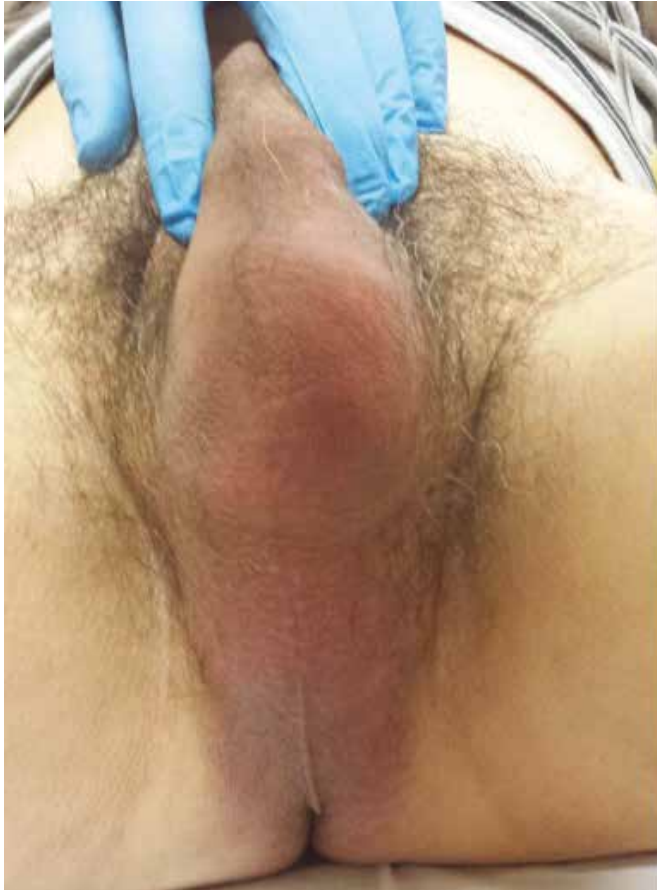

Figure 1: Perineal and scrotal swelling.

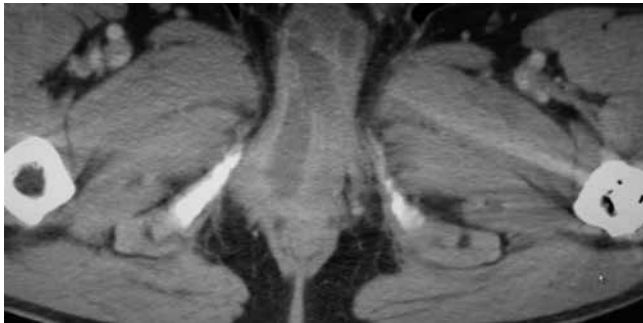


Figure 2: CT scan with fluid collection involving the bilateral cavernosal bodies.

of progression to necrotizing fasciitis. Presentation includes local swelling and pain, and despite clinical suspicion, diagnosis can be confirmed through ultrasound, CT or magnetic resonance imaging (MRI). These techniques are useful not only for diagnosis but also to aid in image-guided aspiration.²⁻⁵ Treatment with aspiration is minimally invasive, resulting in less long-term sequelae like erectile dysfunction, penile deviation or fibrosis of the corpus cavernosum.³⁻⁵ Nevertheless, aspiration has a greater risk of abscess recurrence,⁴ which, in persistent cases, including those treated with surgical drainage, penectomy may be necessary.⁶ In the presented case, the decision of surgical drainage was made

based on the extension of the abscess, which was bilateral and multiloculated. Surgical drainage remains the first line therapy despite the risk of sequelae, namely erectile dysfunction, that may be treated with a penile prosthesis.⁵⁻⁷ After surgical drainage, antibiotics were maintained for 4 weeks, based on antibiotic sensitivity test. The authors decided to maintain the same drug because all the other options were also broad-spectrum intravenous antibiotics. Antibiotherapy was maintained until inflammatory blood test and clinical signs normalization. Identifying causal organisms is important in order to adequate antibiotic therapy that must be given to all patients. ●

Responsabilidades Éticas

Conflitos de Interesse: Os autores declaram a inexistência de conflitos de interesse na realização do presente trabalho.

Fontes de Financiamento: Não existiram fontes externas de financiamento para a realização deste artigo.

Proteção de Pessoas e Animais: Os autores declaram que os procedimentos seguidos estavam de acordo com a Declaração de Helsinquia da Associação Médica Mundial.

Confidencialidade dos Dados: Os autores declaram ter seguido os protocolos do seu centro de trabalho acerca da publicação dos dados de doentes.

Ethical Disclosures

Conflicts of interest: The authors report no conflict of interest. Funding sources: No subsidies or grants contributed to this work.

Financing Support: This work has not received any contribution, grant or scholarship. Protection of Human and Animal Subjects: The authors declare that the procedures followed were in accordance with the regulations of the relevant clinical research ethics committee and with those of the Code of Ethics of the World Medical Association (Declaration of Helsinki).

Confidentiality of Data: The authors declare that they have followed the protocols of their work center on the publication of patient data.

*Corresponding Author/*Autor Correspondente:

Pedro Simões de Oliveira
Avenida Professor Egas Moniz, 1649-035 Lisboa
E-mail: pedrosimoesdeoliveira@gmail.com

Recebido/Received: 2017-05-29

Aceite/Accepted: 2018-04-01

REFERENCES

1. Al-Reshaid RA, Madbouly K, Al-Jasser A. Penile abscess and necrotizing fasciitis secondary to neglected false penile fracture. *Urol Ann.* 2010; 2: 86-8.
2. Palacios A, Masso P, Versos R, Osorio L, Carvalho LF, Soares J, et al. Penile abscess. Case report. *Arch Esp Urol.* 2006; 59: 809-11.
3. Kropman RF, de la Fuente RB, Venema PL, Van Imhoff WL. Treatment of corpus cavernosum abscess by aspiration and intravenous antibiotics. *J Urol.* 1993; 150: 1502-3.
4. Dugdale CM, Tompkins AJ, Reece RM, Gardner AF. Cavernal abscess due to *Streptococcus anginosus*: a case report and comprehensive review of the literature. *Curr Urol.* 2013; 7:5 1-6.
5. Sagar J, Sagar B, Shah DK. Spontaneous penile (cavernosal) abscess: case report with discussion of aetiology, diagnosis, and management with review of literature. *ScientificWorldJournal.* 2005; 5: 39-41.
6. Ehara H, Kojima K, Hagiwara N, Phuoc NB, Deguchi T. Abscess of the corpus cavernosum. *Int J Infect Dis.* 2007; 11: 553-4.
7. Dempster NJ, Maitra NU, McAuley L, Brown M, Hendry D. A unique case of penile necrotizing fasciitis secondary to spontaneous corpus cavernosal abscess. *Case Rep Urol.* 2013: 576146.